

blue<sup>®</sup>m

Case Presentation  
Immediate Implant and soft tissue graft

Dr. Rafael Block Veras

# Immediate Implant and soft tissue graft

case report

## Dr. Rafael Block Veras

### *curriculum vitae*

- 1997 - 2001: Dental School in Curitiba - Brazil - DDS Degree
- 2002-2003: Master of Science in experimental surgery at the University of Sao Paulo – Brazil
- 2003: Curriculum for Oral Surgery and Advanced Implantatology at ILAPEO Neodent in Curitiba - Brazil
- 2003-2005: Private dental office in Curitiba Brazil - together with Dr. Ricardo Kern
- 2005: Scholarship as Researcher in Germany– VDDI Association of the German Dental Industry
- 2006 - 2007: Scholarship for Doctorate – ALBAN Program of the EU.
- 2007-2011: Residency and Specialization in Oral and Maxillofacial Surgery at the Martin Luther University Halle-Wittenberg (Prof. Dr. Dr. J. Schubert)
- 2009: Doctorate (Dr.med.dent.) at the Martin Luther University Halle-Wittenberg (Prof. Dr. Dr. J. Schubert)
- 2009: Second Place at the Dentsply Prize for best Doctorate (Germany, Austria and Swiss)
- 2010: Degree of Oral and Maxillofacial surgeon
- 2011 - 2013: Employed Surgeon at a private clinic in Berlin
- 2013 - 2016: Employed Surgeon at a private clinic in Munich
- 2016: Owner of a Private Practice for Oral Surgery and Implantology in Berlin - Berliner City Chirurgie
- Reviewer for the International Journal of Oral and Maxillofacial Surgery IJOMS since 2011
- Member of the German Association of Oral and Maxillofacial Surgery



Dr. Rafael Block Veras

# Immediate Implant and soft tissue graft

case report

## Anamnesis

Female, 66 years old

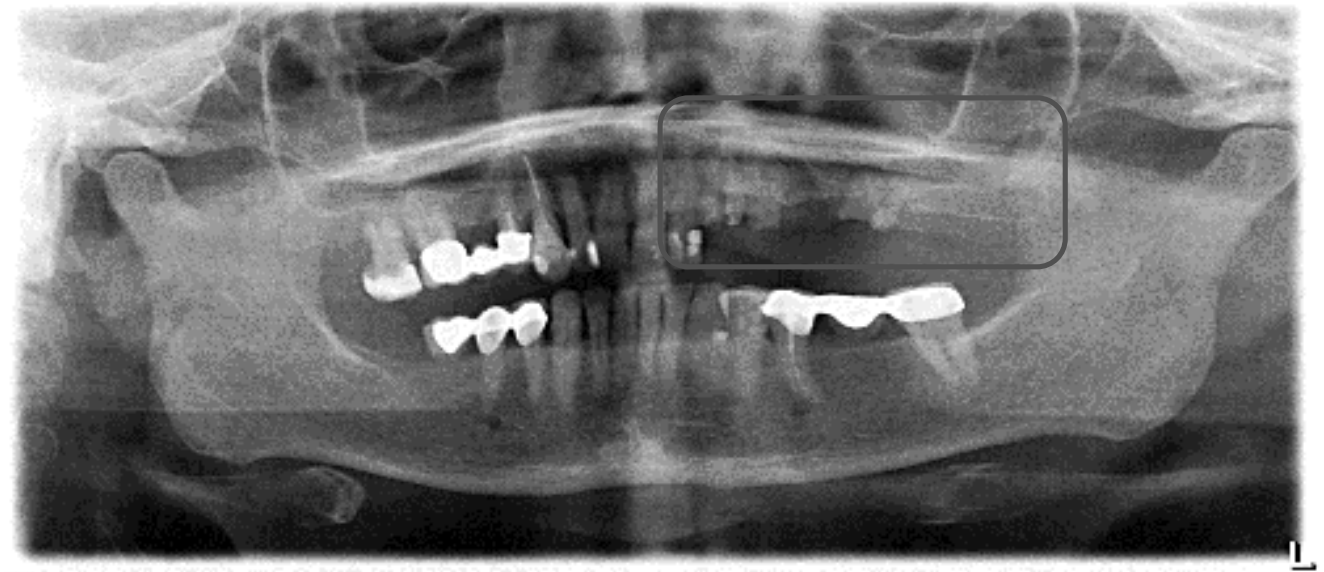
Good oral hygiene

Hypertension

Residual roots 23,24 and 27

Used Material:

- Pericard Membrane
- Autologous Bone
- keratinized soft tissue graft from tuber



25.05.2018

# Immediate Implant and soft tissue graft

case report

## Therapy

Initial therapy

Oral hygiene reinforcement

2x daily rinse with blue®m oxygen Fluid

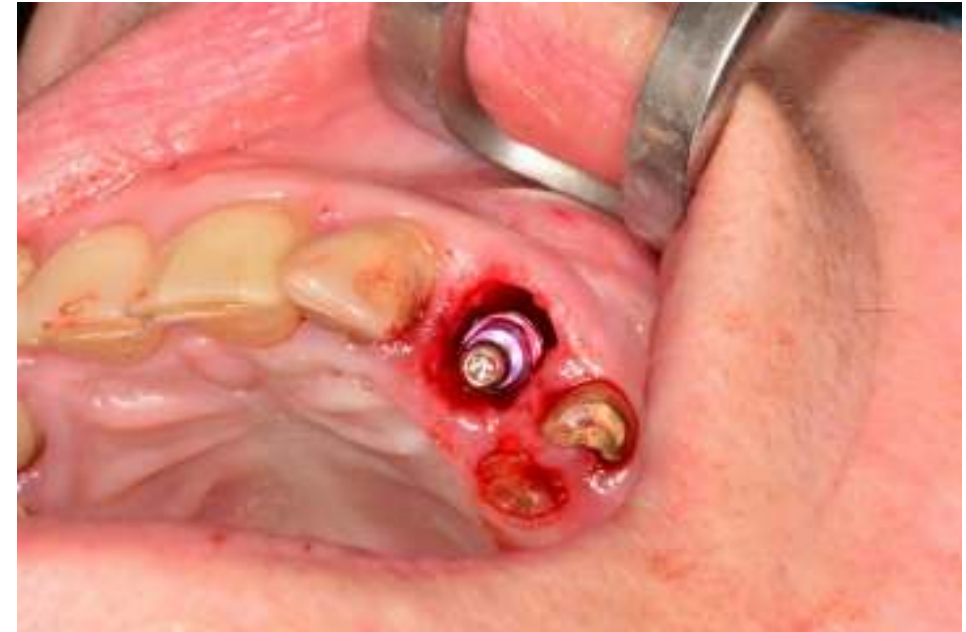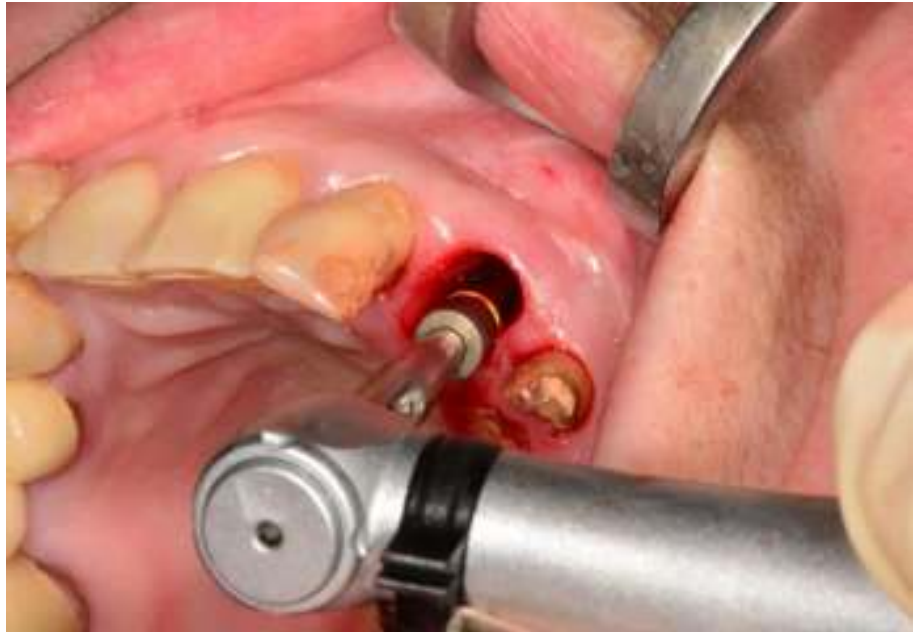## Therapy Plan

- Extraction 23, 25, 27 and immediate Implantation
- Covering of the Implant 23 and 25 with soft tissue graft

# Immediate Implant and soft tissue graft

case report

Extraction and implant preparation

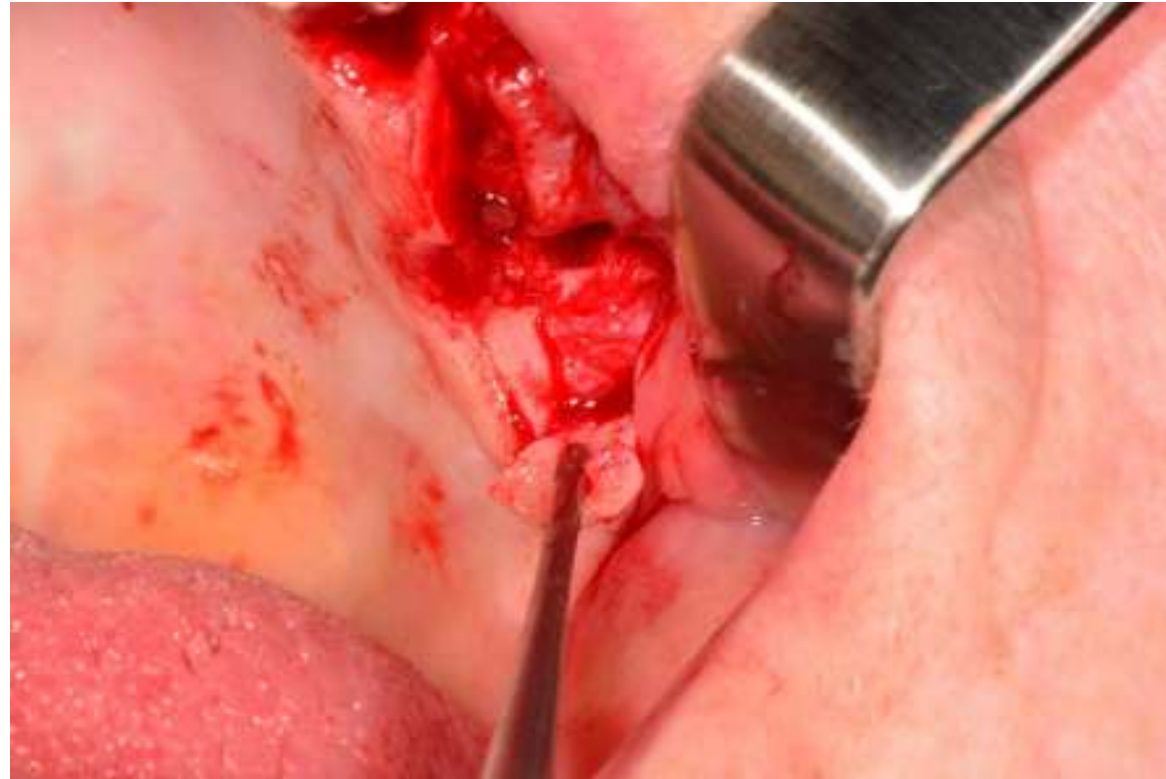


# Immediate Implant and soft tissue graft

case report



Retracting the keratinized graft from the tuber



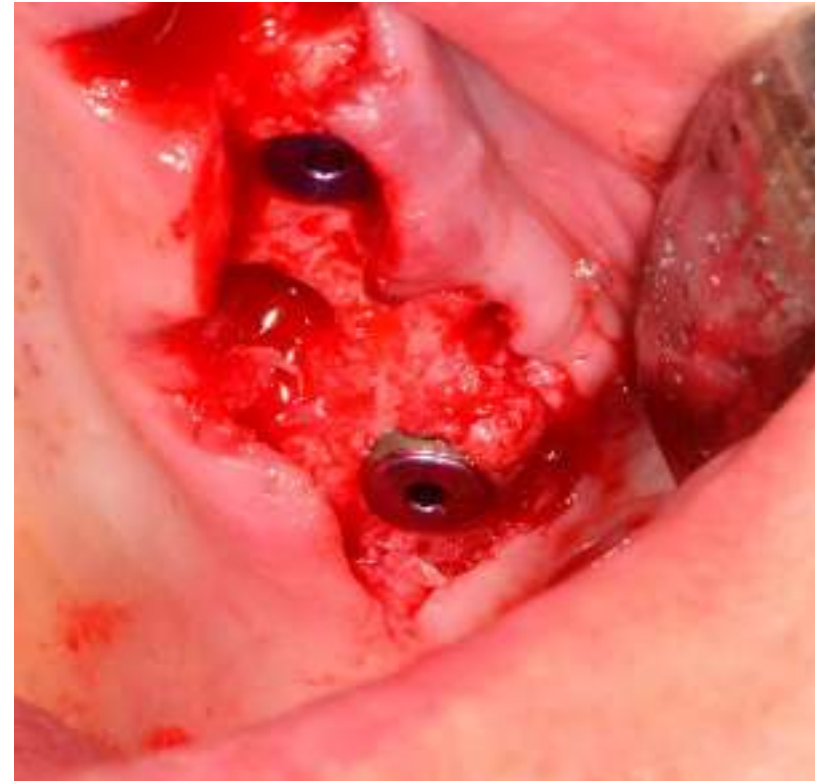
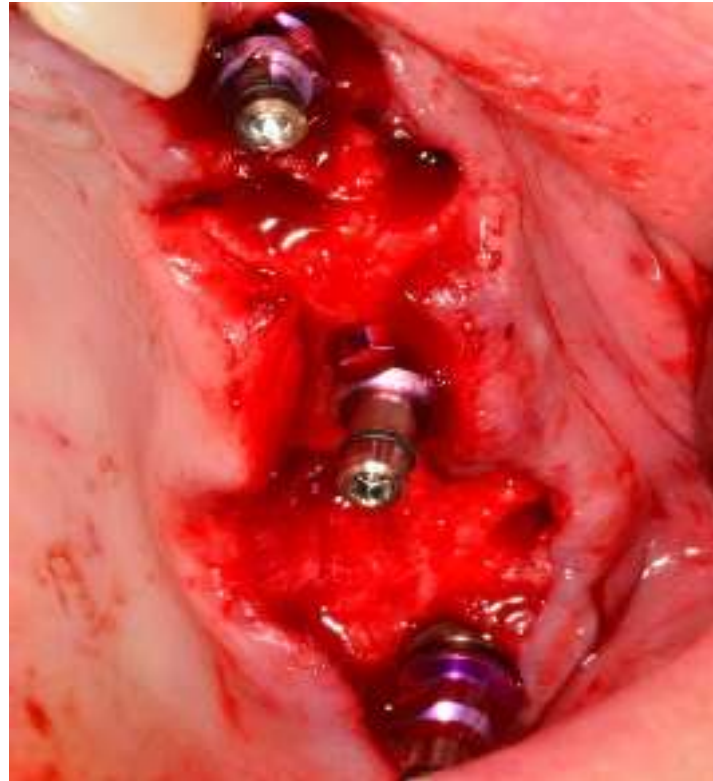
# Immediate Implant and soft tissue graft

case report



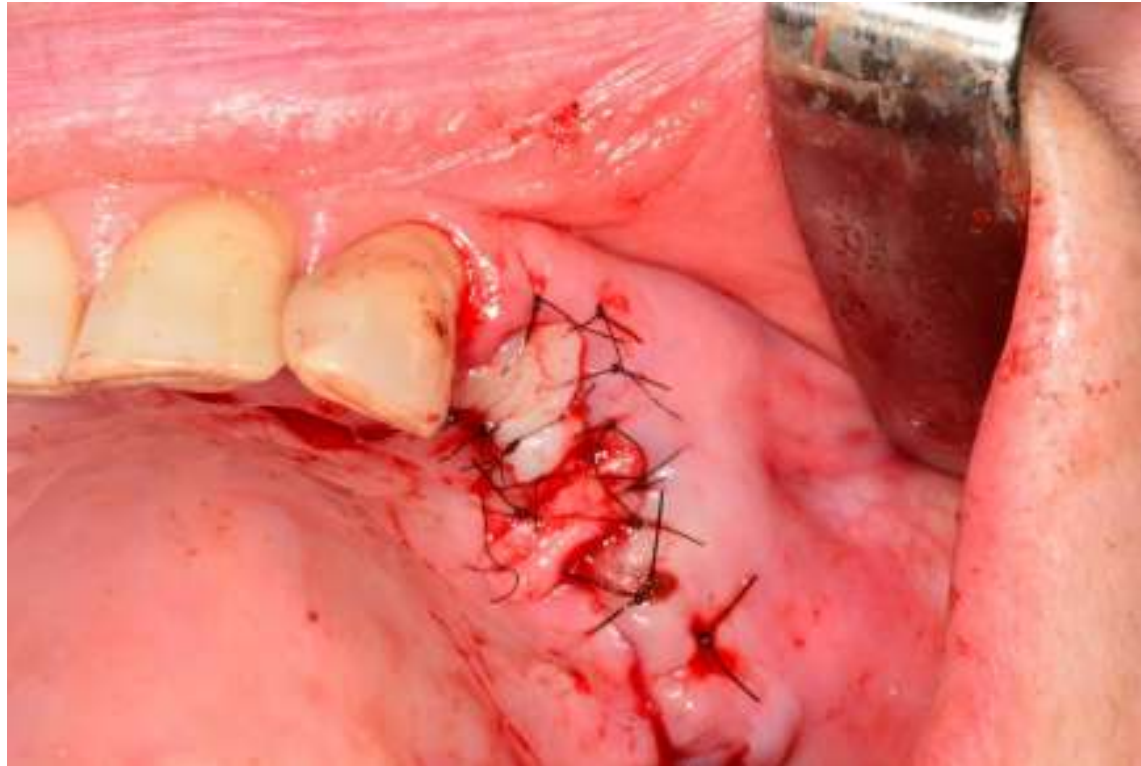
Implant placement



# Immediate Implant and soft tissue graft

case report

Suture and fixation of the graft – note the typical ischemia of the graft



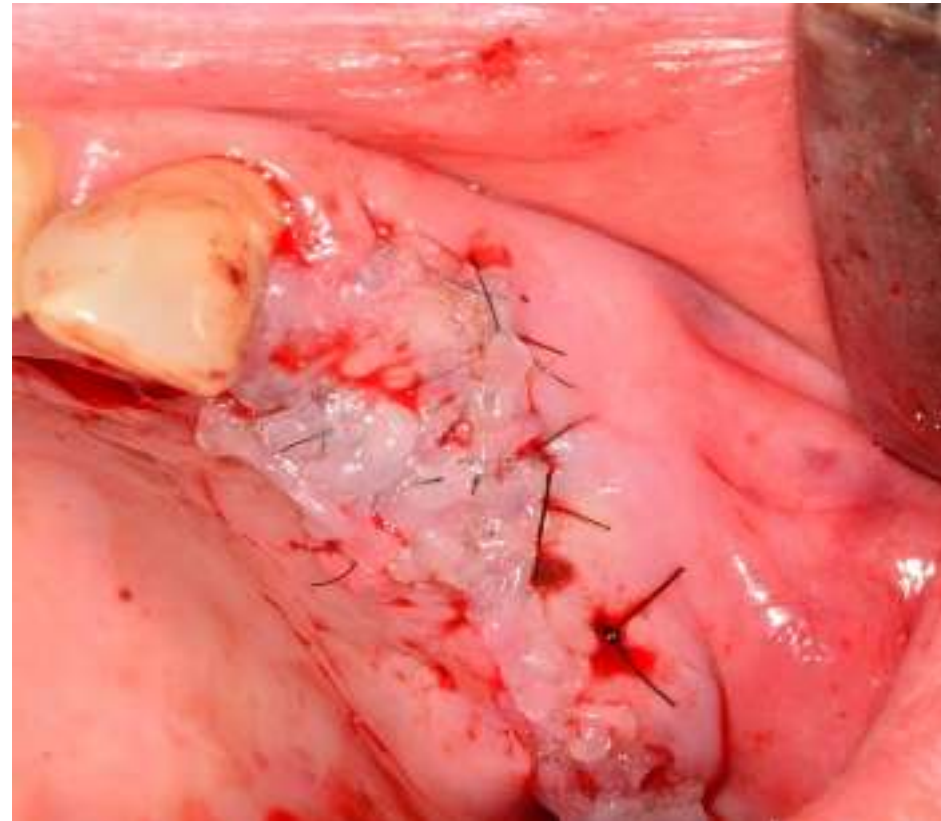


# Immediate Implant and soft tissue graft

case report



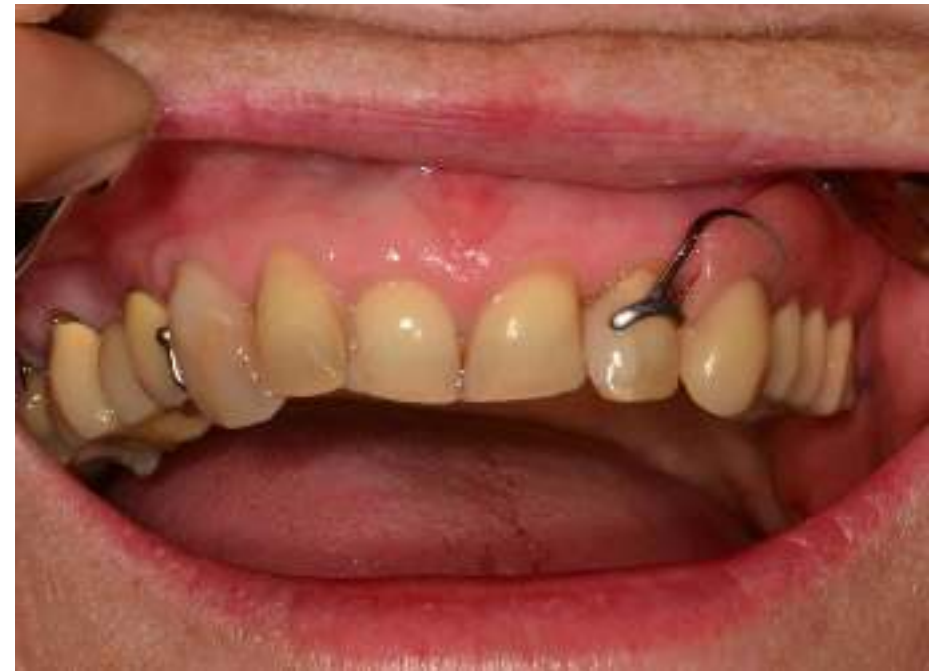Topic application of BlueM oral gel



# Immediate Implant and soft tissue graft

case report

Patient apply the BlueM oral gel at home under the temporary

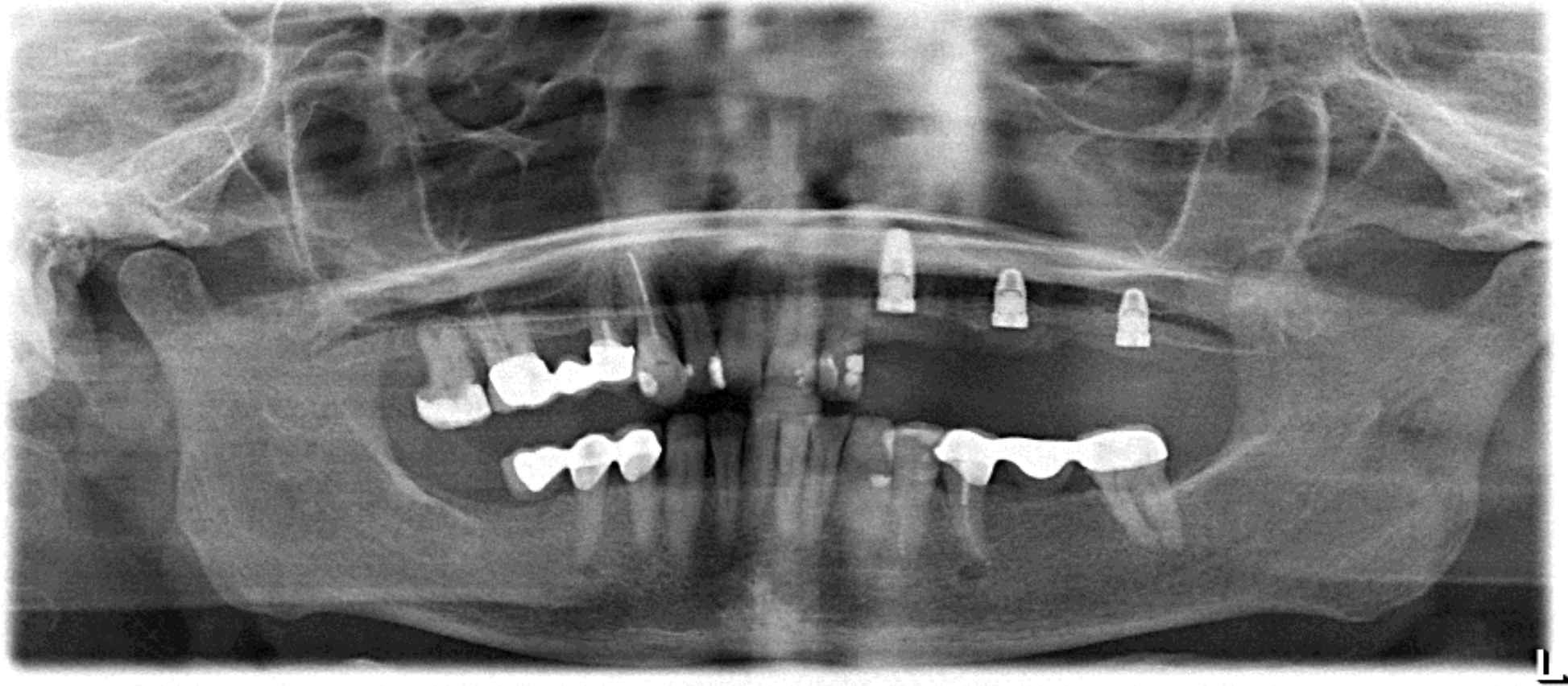


# Immediate Implant and soft tissue graft

case report



Postoperative x-ray

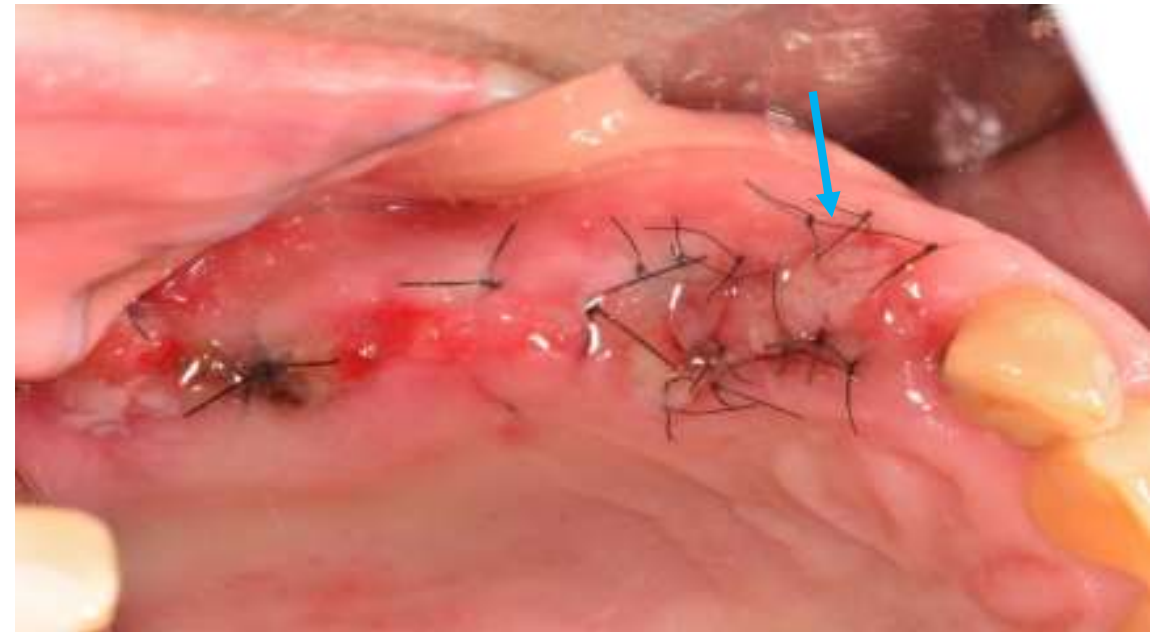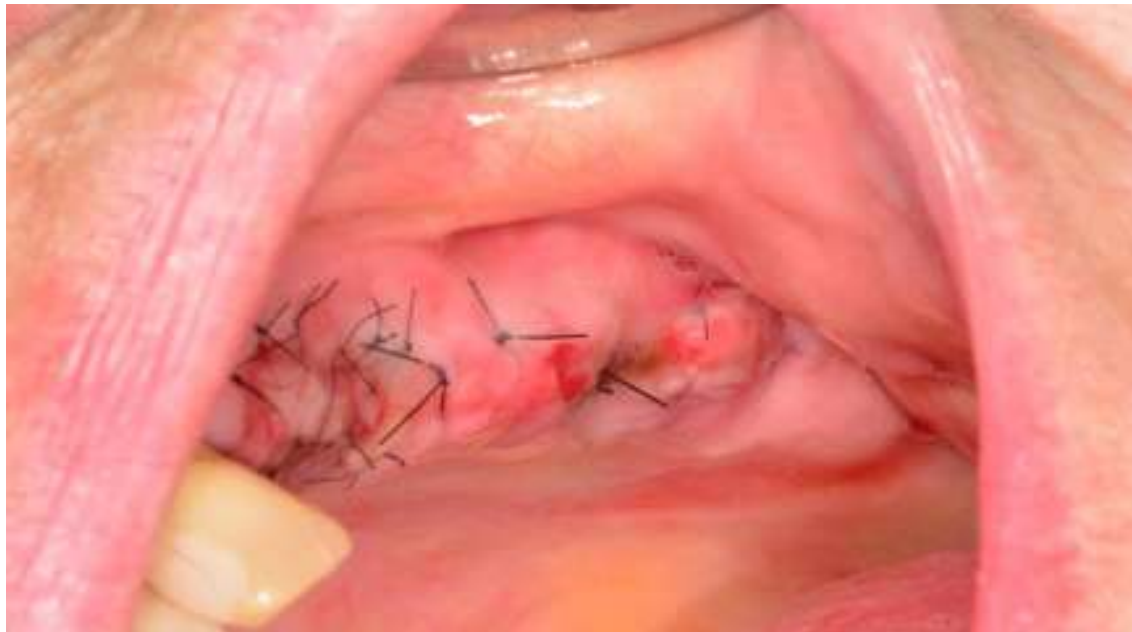


# Immediate Implant and soft tissue graft

case report



Follow up after 3 days – note the revascularisation of the graft

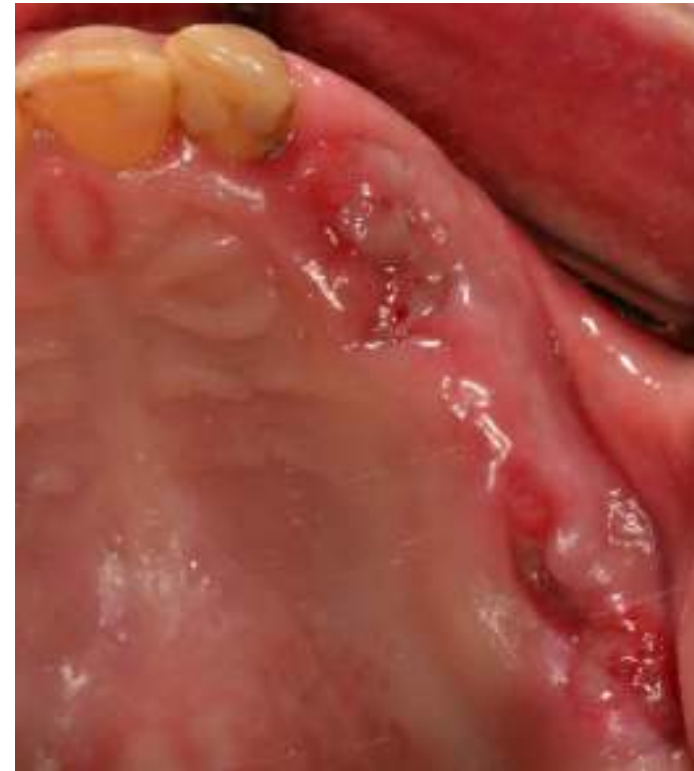
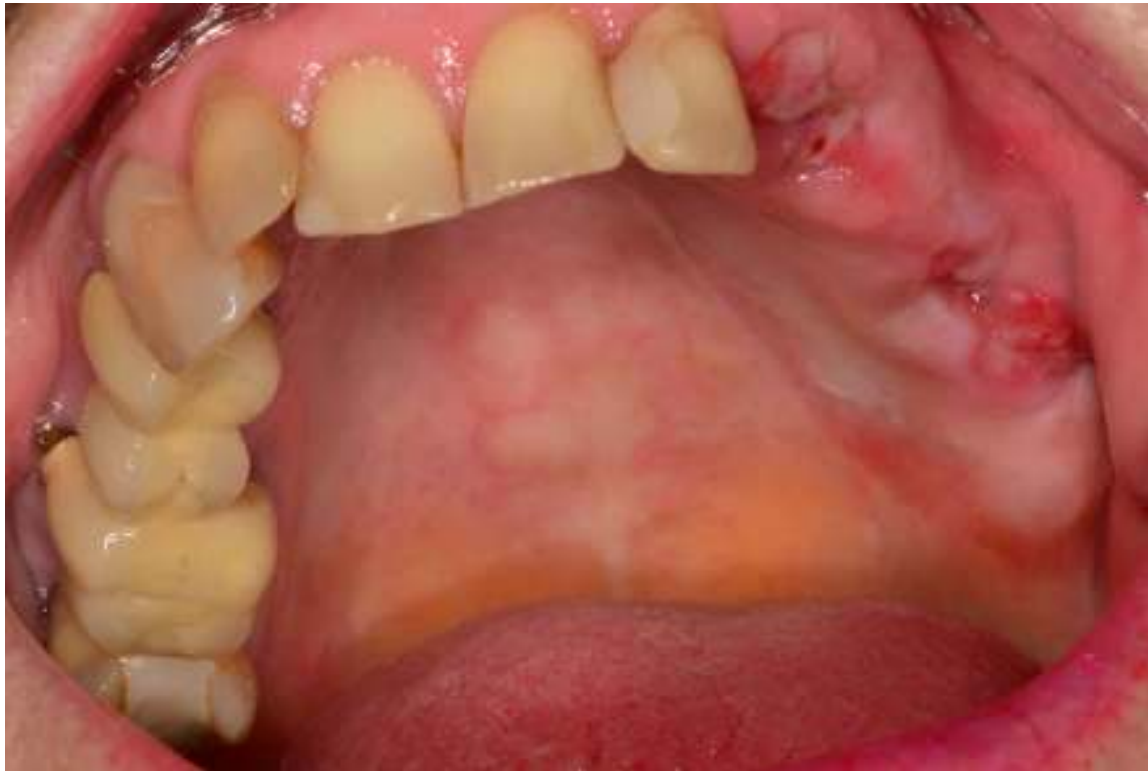


# Immediate Implant and soft tissue graft

case report

Removal of the suture after 7 days

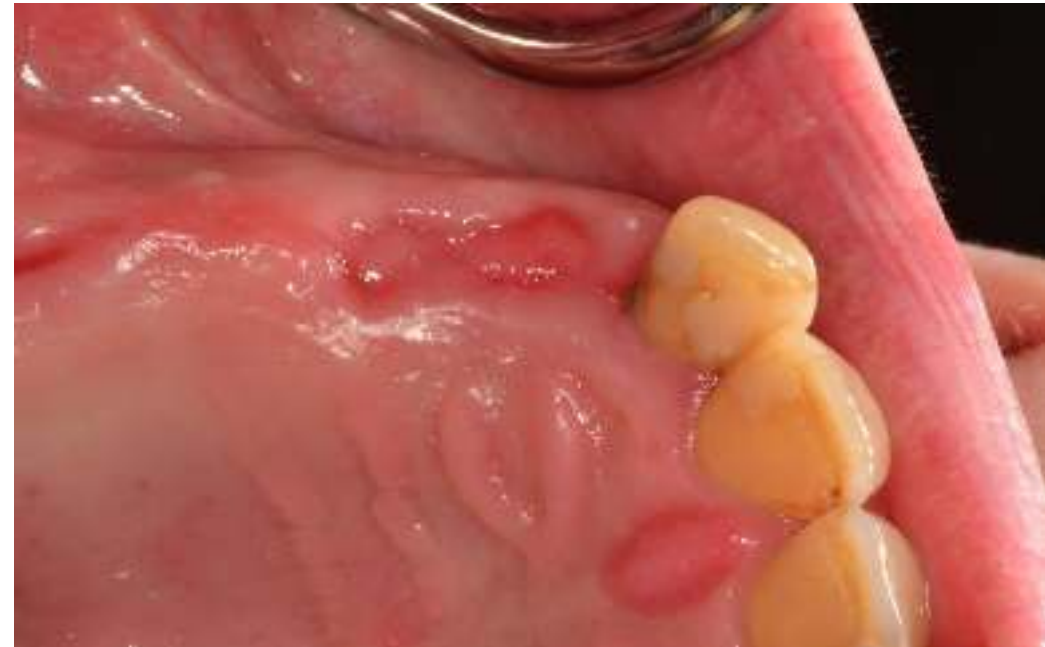
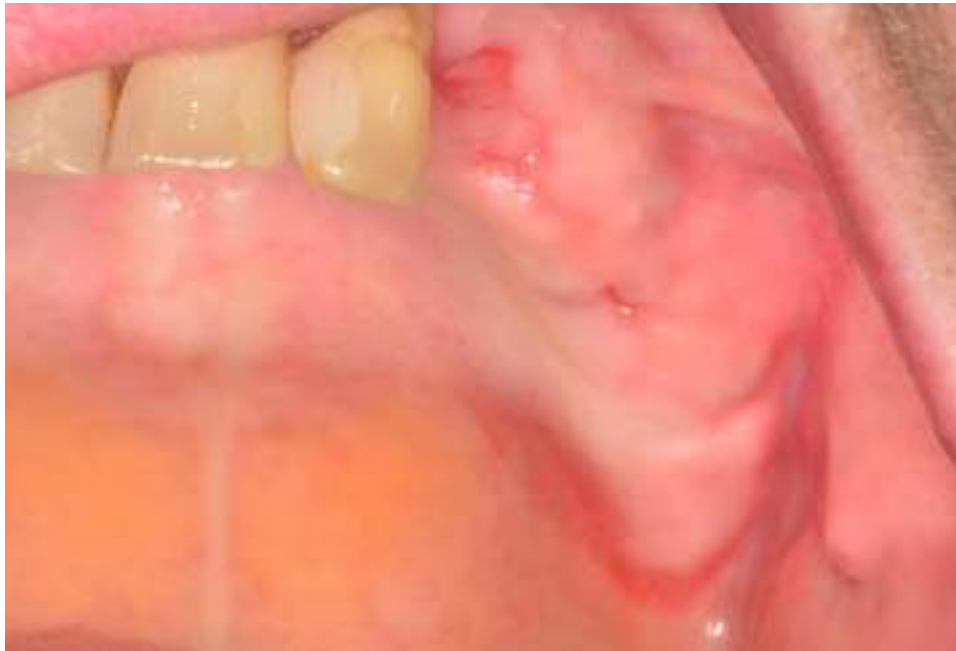
# Immediate Implant and soft tissue graft

case report



Follow up after 4 weeks

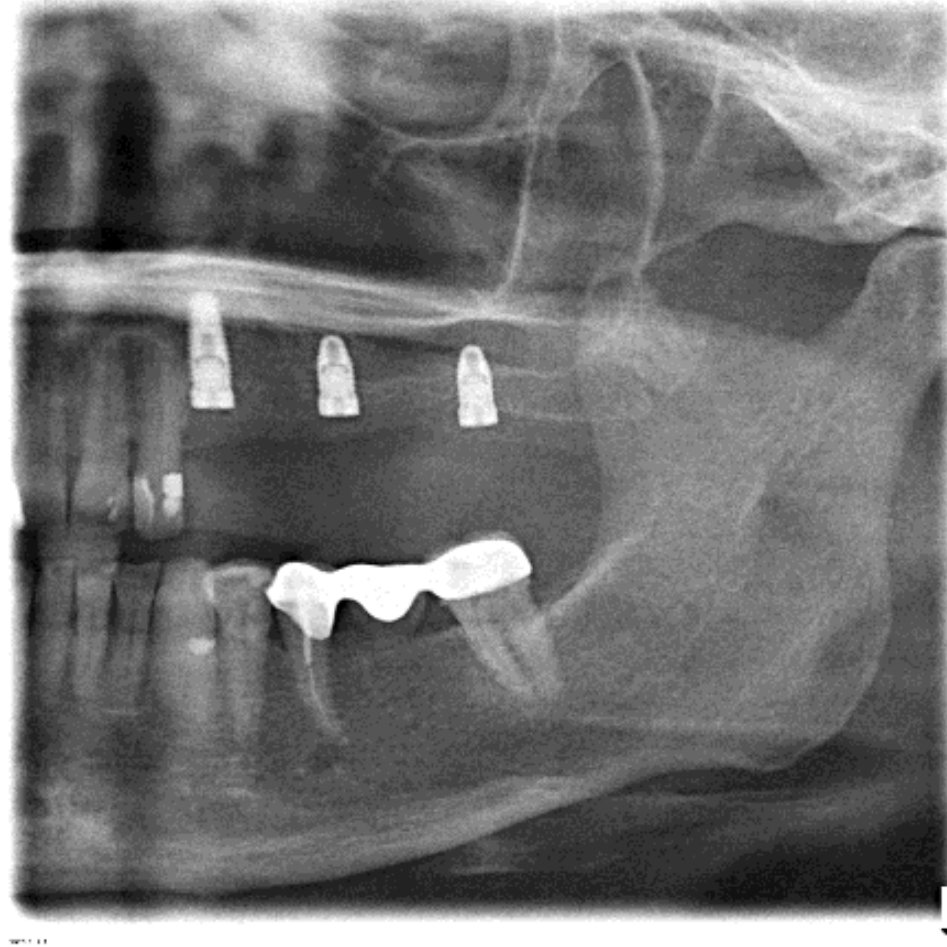




# Immediate Implant and soft tissue graft

case report

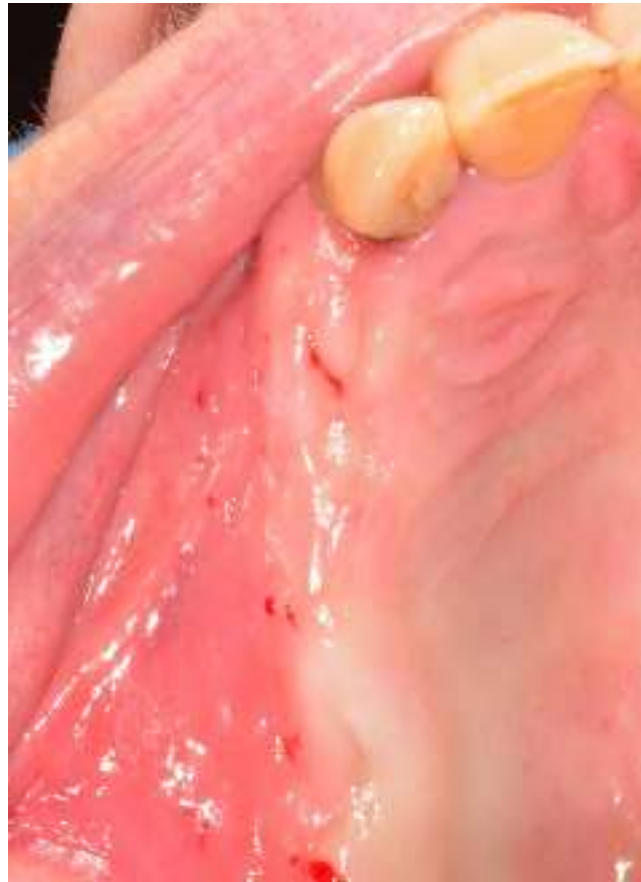Follow up x-ray after 3 months



# Immediate Implant and soft tissue graft

case report

Follow up after 3 months – preparing for re-opening

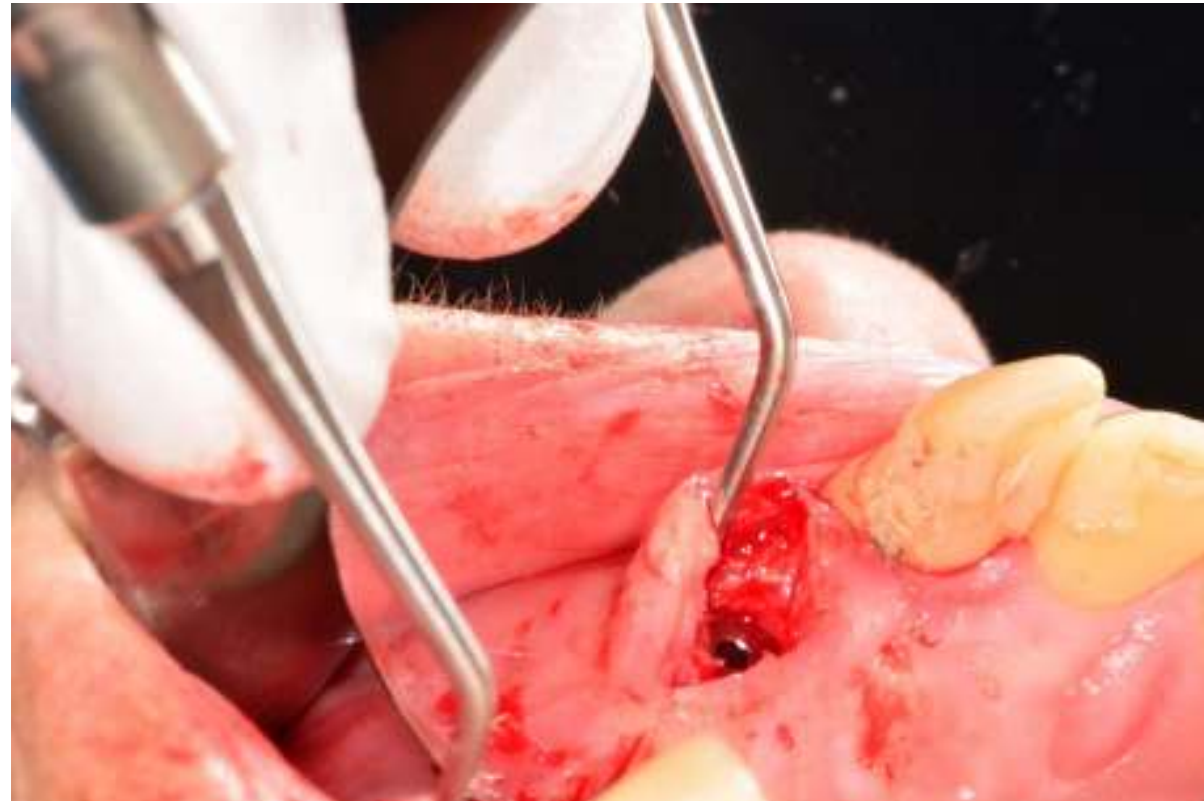

# Immediate Implant and soft tissue graft

case report



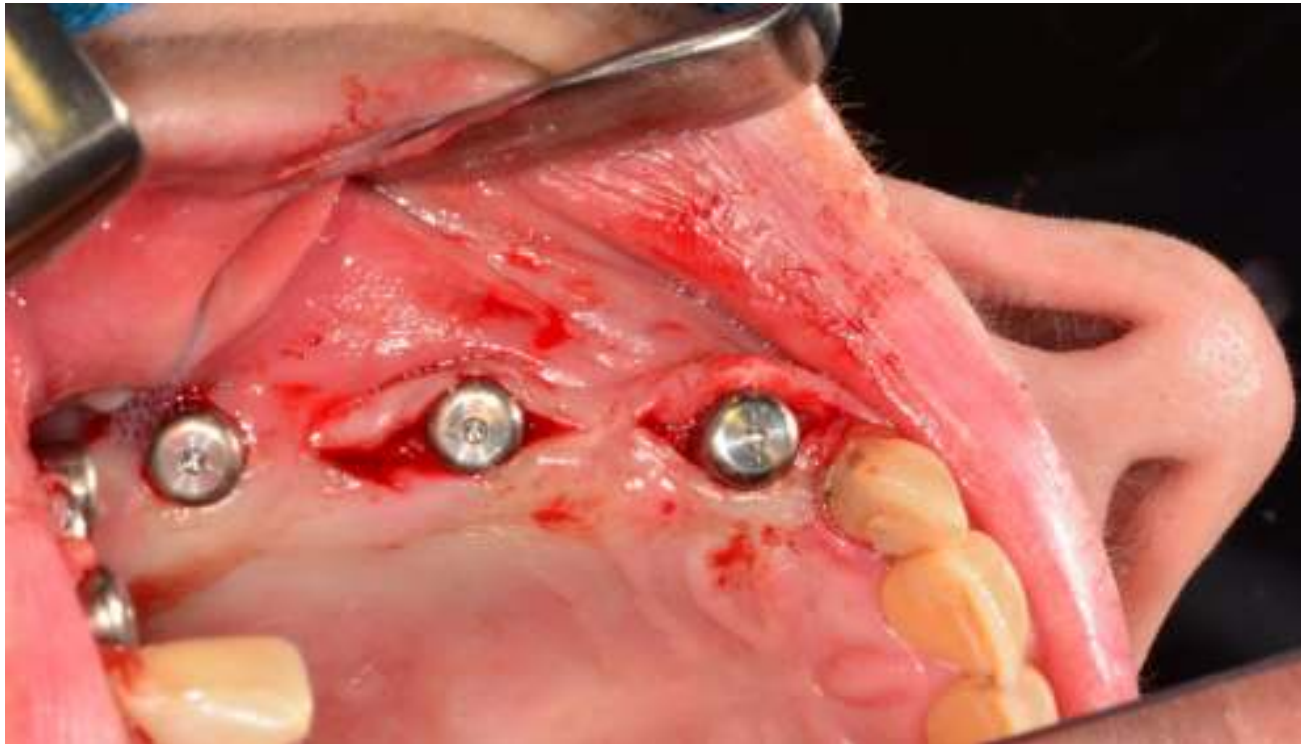Re-opening after 3 months



# Immediate Implant and soft tissue graft

case report

Re-opening after 3 months – note the volume of keratinized tissue

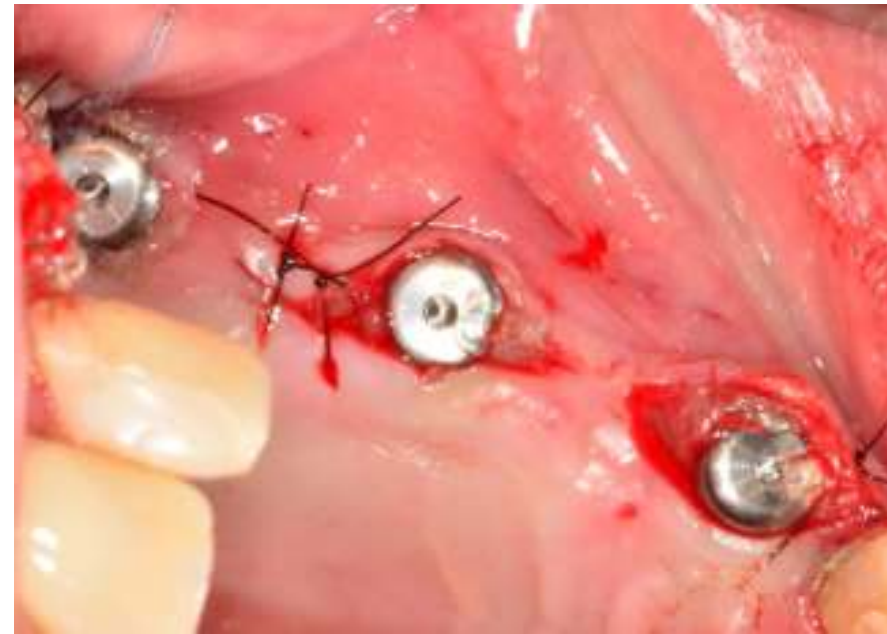
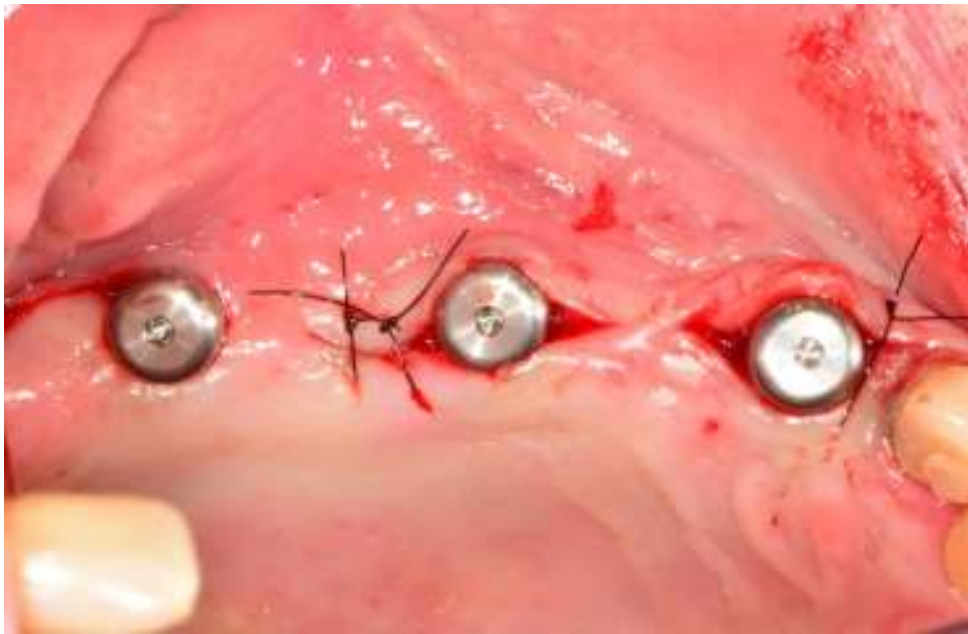

# Immediate Implant and soft tissue graft

case report



Application of BlueM oral gel





# Immediate Implant and soft tissue graft

case report

Follow up after 10 days – ready for the prosthetics!

